



PATIENT

Piper Bryant

SPECIES

Canine

BREED

Yorkie

SEX

FS

AGE

14 y

WEIGHT

15 lb

PRESENTING CLINICAL SIGNS

Grade III/VI left apical murmur. Receiving pimobendan 2.5 mg am, 1.25 mg pm and enalapril 2.5 mg BID.

ECHOCARDIOGRAPHIC FINDINGS

2D, M-mode, and Doppler study.

There is mild left atrial dilation. The mitral valve leaflets are thickened and exhibit systolic prolapse. There is Doppler evidence of mitral regurgitation present. There is mild left ventricular dilation. Left ventricular systolic function is hyperdynamic. The aorta and aortic valve are normal. Right atrial and right ventricular dimensions are normal. The tricuspid valve appears normal. The pulmonary artery and pulmonic valve are normal. No shunting lesions are visualized. No pericardial effusion or cardiac masses are seen.

LA - 28.8 mm
LVIDd - 28.3 mm
LVIDs - 9.8 mm
FS - 65.4%
RA - 14.1 mm
LVOT - 1.20 m/s
RVOT - 1.13 m/s

INTERPRETED BY

Keith Blass, DVM, MS,
DACVIM (Cardiology)

IMAGING PERFORMED BY

Brandi Kurzowski

HOSPITAL NAME

Corfu VC

REFERRING VET

Dr. Greil

INVOICE

DATE

1/29/26

ASSESSMENT/RECOMMENDATIONS

Degenerative mitral valve disease - stage B2

These examinations demonstrate regurgitation of blood across Piper's mitral valve resulting from degenerative valve disease. Secondary to her regurgitation, Piper has mild dilation of both her left atrium and left ventricle, though her left ventricular systolic function is well-preserved. As only mild left heart chamber dilation is present, Piper's current risk for the development of clinical signs secondary to her mitral valve disease, such as coughing, exercise intolerance, syncope, and labored breathing, appears to be relatively low, though careful monitoring for these signs is recommended going forward.

No change in therapy is recommended based on this exam.

A recheck echocardiogram is recommended in 9 months. Thoracic radiographs are recommended if Piper experiences respiratory clinical signs.



PATIENT

Piper Bryant

SPECIES

Canine

BREED

Yorkie

SEX

FS

AGE

14 y

WEIGHT

15 lb

INTERPRETED BY

Keith Blass, DVM, MS,
DACVIM (Cardiology)

IMAGING PERFORMED BY

Brandi Kurzowski

HOSPITAL NAME

Corfu VC

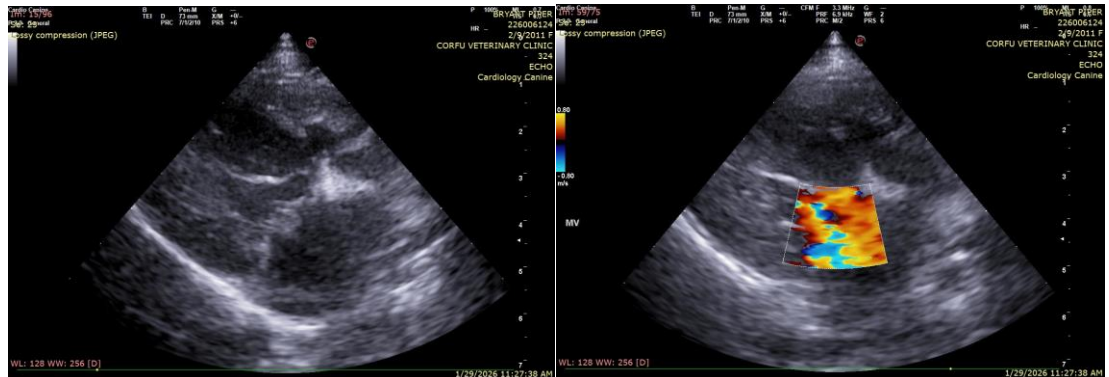
REFERRING VET

Dr. Greil

INVOICE

DATE

1/29/26



The information and recommendations provided are based on the images presented by the referring veterinarian/sonographer. No evaluation can be communicated regarding pathology that was not visible in the image/video clips provided.

Thank you for this referral. If the clinical or image interpretation does not parallel your findings or if I can be of any further assistance please contact me.

Keith Blass, DVM, MS, DACVIM (Cardiology)

info@SonoPath.com